

4-28-2023

Treatment of Oral Vascular Malformations with Ethamolin: A Report of Two Cases

Maria Clara de Moura Santos Coelho Ferreira

Departamento de odontologia, Universidade de Taubaté, Taubaté, São Paulo, Brazil,
mariaclaracoelho36@gmail.com

Marco Vinícius de Sales Lima

Departamento de odontologia, Universidade de Taubaté, Taubaté, São Paulo, Brazil,
victor.nauta@outlook.com

Anna Laura Almeida Barreto

Departamento de odontologia, Universidade de Taubaté, Taubaté, São Paulo, Brazil,
annalabarreto@gmail.com

Dárcio Kitakawa

Departamento de odontologia, Centro Universitário de Braz Cubas, Mogi das Cruzes, São Paulo, Brazil,
dkitakawa@yahoo.com

Alexandre do Prado Scherma

Departamento de odontologia, Universidade de Taubaté, Taubaté, São Paulo, Brazil,
alexandre.pscherma@unitau.br

Follow this and additional works at: <https://scholarhub.ui.ac.id/jdi>



Part of the [Dental Hygiene Commons](#), [Health Economics Commons](#), [Oral and Maxillofacial Surgery Commons](#), [Oral Biology and Oral Pathology Commons](#), and the [Pharmacy Administration, Policy and Regulation Commons](#)

Recommended Citation

Coelho Ferreira, M. d., de Sales Lima, M., Almeida Barreto, A., Kitakawa, D., Scherma, A. d., Peralta, F., & de Carvalho, L. d. Treatment of Oral Vascular Malformations with Ethamolin: A Report of Two Cases. *J Dent Indones.* 2023;30(1): 57-61

This Case Report is brought to you for free and open access by the Faculty of Dentistry at UI Scholars Hub. It has been accepted for inclusion in *Journal of Dentistry Indonesia* by an authorized editor of UI Scholars Hub.

Treatment of Oral Vascular Malformations with Ethamolin: A Report of Two Cases

Cover Page Footnote

CONFLICT OF INTEREST Authors report no conflict of interest.

Authors

Maria Clara de Moura Santos Coelho Ferreira, Marco Vinícius de Sales Lima, Anna Laura Almeida Barreto, Dárcio Kitakawa, Alexandre do Prado Scherma, Felipe Peralta, and Luis Felipe das Chagas e Silva de Carvalho

CASE REPORT

Treatment of Oral Vascular Malformations with Ethamolin: A Report of Two Cases

Maria Clara de Moura Santos Coelho Ferreira¹, Marco Vinícius de Sales Lima¹, Anna Laura Almeida Barreto¹, Dárcio Kitakawa², Alexandre do Prado Scherma¹, Felipe Peralta³, Luis Felipe das Chagas e Silva de Carvalho^{1,2*}

¹*Departamento de odontologia, Universidade de Taubaté, Taubaté, São Paulo, Brazil*

²*Departamento de odontologia, Centro Universitário de Braz Cubas, Mogi das Cruzes, São Paulo, Brazil*

³*Universidade Sociedade Educacional de Santa Catarina, Santa Catarina, Brazil*

*Correspondence e-mail to: luisfelipecarvalho@hotmail.com

ABSTRACT

A hemangioma is a benign vascular neoplasm, relatively common in the head and neck. In the oral region, it affects the tongue, gums, mucosa, palate, and lip. Its size can vary from millimeters to centimeters, characterized as a purplish or reddish lesion. The present study aims to present two clinical cases of hemangiomas, the first of a male patient treated by sclerotherapy and the second of a female patient in which she was treated with ethamolin and later surgical treatment. It was concluded that sclerotherapy, in addition to being a safe treatment, managed to drastically reduce the initial size of the lesions present in this article.

Key words: ethamolin, oral hemangioma, vascular malformation

How to cite this article: Ferreira MCMSC, Lima MVS, Barreto ALA, Kitakawa D, Scherma AP, Peralta F, Carvalho LFCS. Treatment of oral vascular malformations with ethamolin: A report of two cases. *J Dent Indones.* 2023;30(1):57-61

INTRODUCTION

A hemangioma is a benign neoplasm of endothelial cells common in the head and neck region, usually asymptomatic, with a lesion with defined edges, soft to the touch, raised or flat, with a smooth or nodular surface with a red or purplish color. It usually has a high temperature in relation to the adjacent regions, and can compromise aesthetics and physiological function depending on the location and size of the lesion. Although less frequent, hemangiomas can occur in the oral and perioral cavities, especially in the lips, tongue, oral mucosa, gums, and palate.¹⁻⁴

Hemangiomas can affect both men and women, but there is a higher prevalence in female patients.^{1,3} The literature indicates that the high incidence of hemangiomas occurs in newborns and children, but some cases are found in adult patients.⁴ For the correct diagnosis, it is important to observe the clinical characteristics and history of the lesion.¹ For the best approach to cases with a suggestive or inconclusive diagnosis, it is important to perform imaging tests such

as Doppler ultrasonography and magnetic resonance imaging.⁵ The treatment of a hemangioma depends on the patient's age, the size and location of the lesion, the stage of evolution, and also its nature (venous or arterial). There are several types of treatment such as sclerotherapy, surgical removal, the use of corticosteroids, laser surgery, embolization and the use of chemotherapeutic agents. Surgery is one of the most frequently used procedures for minor lesions, but it is necessary to assess each case for the risk of hemorrhage and complications such as incomplete removal and aesthetic problems.^{1,3,4,6} However, sclerotherapy is a well-regarded method for small cases of hemangiomas, mainly involving sites with aesthetic impact.¹

The sclerosing agent monoethanolamine oleate (trade name "Ethamolin") is widely used to treat varicose veins with great success. It is a sclerosing agent that acts by irritating the intimal endothelial layer of the vein and produces a dose-related sterile inflammatory response. This results in fibrosis of the vessel wall and possible

occlusion of the vein. The substance also diffuses rapidly through the venous wall and produces a dose-related extravascular inflammatory reaction.⁷ After the applications, some very specific adverse reactions can be observed, mainly between the first and third day after sclerotherapy. The most common reactions reported by patients are: pain and burning at the site, swelling, and purplish coloration. Many studies also show the effectiveness of Ethamolin for the treatment of hemangiomas and vascular malformations located in the oral mucosa.^{4-6,8}

The present article aims to present two cases of hemangiomas, the first of which is a 13-year-old male patient with a purplish lesion of approximately 3 cm in the gum, in which ethamolin was applied in two sessions and as a result we had complete regression of the lesion. The second case concerns a 28-year-old female patient with a purple nodule on the tongue of 1.8 cm in diameter in which ethamolin was applied and later treated with surgery, where it was observed that the lesion significantly reduced from the original size and favored surgical treatment resulting in total regression of the lesion.

CASE REPORT

The first case concerns a 13-year-old leukoderma male patient, who attended the CK Stomatology clinic in the city of São José dos Campos - Brazil, complaining of difficulty whilst chewing and swallowing in addition to the aesthetic complaint. During the clinical examination, a purplish nodular lesion of approximately 3 cm in diameter was observed, involving the gingiva of the buccal and lingual surfaces in the region of teeth 32, 33, and 34 (Figure 1). The vitro pressure maneuver was performed, which consists of pressing a glass against a lesion, in this case, when the lesion was pressed, the lesion whitened, confirming the diagnostic hypothesis of a hemangioma. We opted for the application of ethamolin in two sessions because in this case the surgical procedure could leave aesthetic sequelae in the gums. In the first session, 1.5 ml of ethamolin was applied by intravascular injection (Figure 2) and after seven weeks of application, 80% of the lesion regressed (Figure 3). The patient returned for the second session 21 days after the first application, in which 0.4 ml of the substance was applied. The lesion has completely regressed, the patient is under observation, and there is no recurrence of the lesion (Figure 4).

The second case is a 28-year-old leukoderma female patient with no harmful habits who also attended the CK Stomatology clinic in the city of Mogi das Cruzes - Brazil, with a 1.8 cm diameter purplish nodule (Figure 5). In anamnesis, the only complaint was aesthetics. The vitro pressure maneuver was also performed to confirm the diagnosis of a hemangioma. The application of ethamolin and subsequent surgery

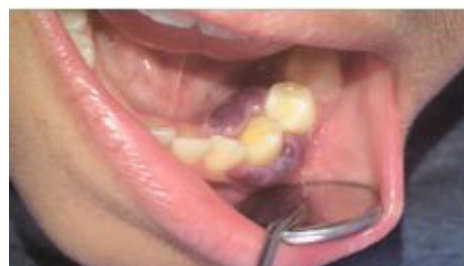

Figure 1. Lesion on the region of the teeth 32#, 33# and 34#, with approximately 3cm in diameter.

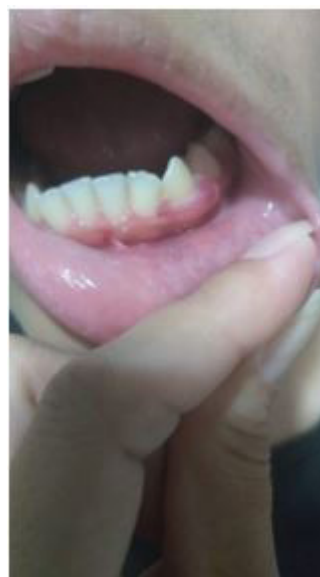

Figure 2. After application of 1.5 ml of ethamolin.

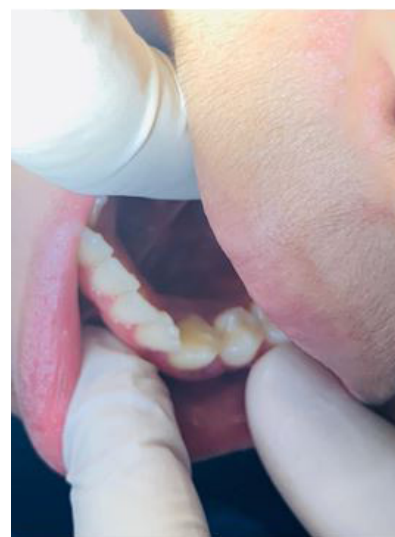


Figure 3. After 7 days from the first session.

was proposed. In the first session, 1.10 ml of the substance was applied and it was observed that in the following weeks the lesion reduced significantly from the original size, favoring surgical treatment (Figure 6 and 7). After three weeks of application, surgery and excisional biopsy were performed, and the result of the biopsy also confirmed the diagnosis of a hemangioma.

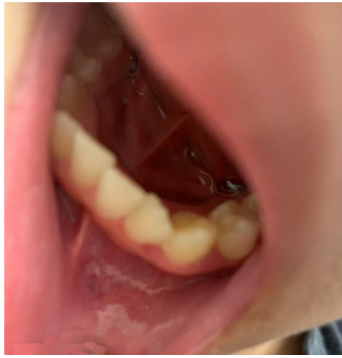


Figure 4. After the second session.

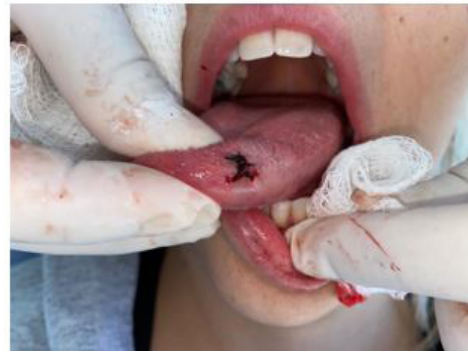

Figure 7. Excisional biopsy of the lesion.

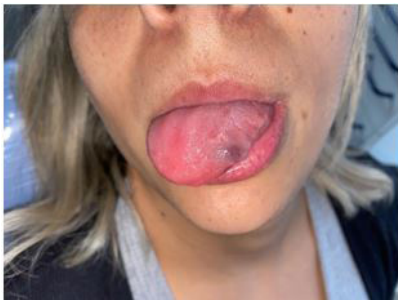

Figure 5. Lesion on the lingual dorsum, with around 1.8cm of diameter.

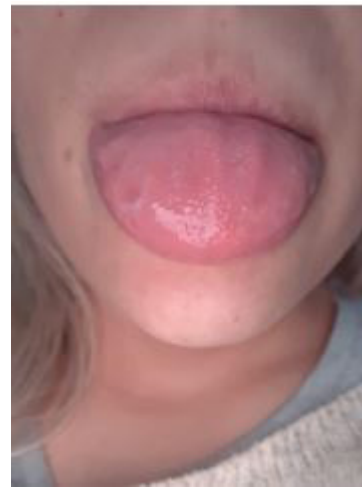

Figure 8. After 2 months of surgical procedure.

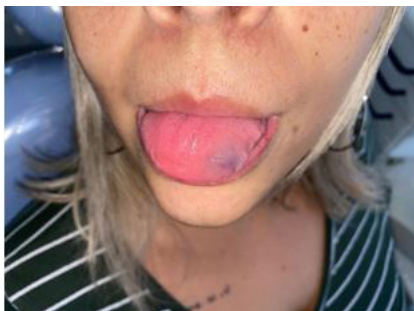

Figure 6. After application of 1.2ml of ethamolin.

The lesion regressed 100% and there were no signs of wound healing 2 months after the procedure (Figure 8). The patient is in preservation and has no recurrence of the lesion.

DISCUSSION

Hemangiomas are benign vascular lesions, common in the head and neck region since 60% of hemangiomas occur in these regions. In the oral region, the most affected sites are the lips, the tongue, the oral mucosa, the gums, and the palate. There is a prevalence of this lesion in females. As reported in both cases, hemangiomas generally present as asymptomatic nodular lesions, elevated or flat, sessile or pedunculated and with a soft, palpable consistency. They vary in size, reaching several centimeters, and can even generate facial asymmetries. These lesions may present themselves as red or purple.^{1,3,7,8}

In 1982, Mulliken and Glowackil classified vascular lesions into two groups: hemangiomas and vascular malformations. Hemangiomas are considered to be true vascular tumors that show rapid growth due to endothelial proliferation, while vascular malformations are the result of vascular or lymphatic changes and do not exhibit an increase in the endothelium.⁴⁻⁶ Histologically, a hemangioma can be classified as capillary and cavernous. The capillary type has several capillaries located under a connective tissue called stroma, and the cavernous type is composed of large and thin vessels that are lined with endothelial cells.²

Some lesions are clinically similar to hemangiomas, so it is necessary to know how to differentiate them. The differential diagnosis includes: Kaposi's sarcoma, Sturge Weber syndrome, angiosarcomas, angiomyolipoma, hemangiosarcoma, pyogenic granuloma, squamous cell carcinoma, peripheral ossifying fibroma, chronic inflammatory gingival hyperplasia, and granulomatous epulis.^{2,3,7,9} In the clinical cases presented by Gill *et al.* and Kumari *et al.* the clinical characteristics of the lesions resembled lesions of pyogenic granulomas,^{2,10} and in the case reported by Henriques *et al.* the lesion resembled

a lipoma,⁹ but in the histopathological report and microscopy, the diagnosis of a hemangioma was confirmed. For Kumari et al. and Henriques et al., the best diagnostic method in these cases would be histopathological exams.^{9,10}

For a conclusive diagnosis of a hemangioma, a complete medical and dental history is necessary, including the beginning of the lesion, its progression, the presence of bleeding or not and the functional impact.¹¹ Therefore, the diagnosis is clinical, often using vitreous pressure, which consists of a semitechnical maneuver in which a glass plate is pressed against the lesion. If the lesion becomes whitish, the diagnostic hypothesis of a hemangioma is confirmed, which occurred in the cases presented in this article.

In cases where the clinical diagnosis is inconclusive or in cases where the lesions are close to vital anatomical structures, complementary exams, especially radiographic examinations, and sometimes computed tomography and magnetic resonance imaging, which assist in the visualization of the extent of the lesion³ are necessary. Radiographically, the lesion may appear as a radiolucent image with the appearance of honeycomb or soap bubbles. According to Jain *et al.*, for a definitive diagnosis, diascopy, ultrasonography with Doppler and magnetic resonance can be implemented.¹²

The treatment of a hemangioma depends on the patient's age and the location and extent of the lesion. Treatment modalities include corticosteroid therapy, use of sclerosing agents, surgical excision and laser therapy, with each technique having advantages and disadvantages.^{8,12,13} Radiotherapy and laser therapy can be used to reduce the size of the lesion, however they are not the therapeutic modalities of first choice due to the adverse effects caused to the adjacent normal tissues and the possible presence of scarring at the end of the therapy.¹² Minimally invasive surgery and minimal postoperative pain are some of the advantages of laser therapy.¹³

For Abdyli *et al.*, surgical treatment offers some advantages as it allows microscopic diagnosis and better chances of a cure, but it offers the risk of bleeding and may compromise functions such as speech and swallowing.¹³ It is considered by the authors as the last treatment option for a hemangioma due to the possibility of recurrence and postoperative scarring and trans-operative bleeding.¹³ According to Ciancio *et al.*, although surgical treatment allows histopathological diagnosis, this technique should be performed preferably on lesions with suspected malignancy, as this treatment can cause discomfort for the patient and the presence of postoperative scarring.¹⁴

It is important to be careful when performing surgical treatment because of the risk of bleeding in the trans and postoperative period.⁷ In most childhood hemangiomas, lesions can be treated only with clinical observation, as they tend to regress. In cases with ulceration, functional limitations, and bleeding, other treatments are indicated, such as the use of steroids, propranolol, laser therapy, steroid injections, and surgery.¹¹

Another treatment modality that has already been mentioned in this article is sclerotherapy. Sclerotherapy induces an inflammatory process that replaces the vascular component with fibrosis and is usually performed in cases of hemangiomas that present a risk of bleeding and impaired physiological and aesthetic functions.¹ There are several sclerosing agents available on the market, such as ethanolamine oleate (ethamolin), morrhuate sodium, sodium tetradecyl sulfate, sodium silicate, and hypertonic glucose solution.^{1,4,8}

The advantages of sclerotherapy in relation to other techniques are: simplicity and safety of application, low cost, it does not require special devices, and the patient does not need to be admitted to perform the procedure.^{13,15} Sclerotherapy, in some cases, can completely regress vascular lesions.^{4,5,13} It is considered an effective technique and an excellent tool for lesions where the surgical procedure could compromise aesthetically.¹³

It is important to note that the sclerosing agent needs to be administered in the center of the lesion, using an insulin needle in order to avoid necrosis of adjacent tissues.^{4,8} The technique is contraindicated in uncontrolled diabetic patients, in pregnant women, and in regions with secondary infection,^{1,4,8} complications include tissue necrosis, and anaphylactic reactions^{1,4} and the amount of sclerosing agent depends on the size of the injury, however, it should not exceed 2 ml per session.^{4,15}

In the first case described, only ethamolin was applied because the surgical treatment could compromise the aesthetic function and in the second case, ethamolin was used in association with the surgical treatment because the surgery would not compromise the aesthetic function, as it did not, since the patient did not present a scar 2-months following the operative period. In both cases, no complications were observed.

In order to determine the best treatment for cases of hemangiomas, the size and location of the lesion, age, and systemic conditions of the patient should be evaluated, and it is essential that the dentist knows about pathologies, diagnostic methods, and indications and contraindications for treatments.¹⁵

CONCLUSION

Although benign, hemangioma lesions can result in unpleasant aesthetic conditions for the patient, in addition to being truly uncomfortable when it affects the mucosa and tongue of the oral cavity. Hemangiomas within the oral cavity are a rare manifestation, therefore, reporting safe treatments, which are easily accessible and have satisfactory results becomes a relief for patients and an important support technique for dentists. Thus, the cases reported here show that sclerotherapy performed with the drug ethamolin is a viable indication of treatment for adult patients, with successful results. Surgical intervention, however, must be evaluated with caution, also being an ally to the treatment of lesions that need removal.

CONFLICT OF INTEREST

Authors report no conflict of interest.

REFERENCES

1. Fernandes DT, Elias RA, Santos-Silva AR, Vargas PA, Lopes MA. Benign oral vascular lesions treated by sclerotherapy with ethanolamine oleate: A retrospective study of 43 patients. *Med Oral Patol Oral Cir Bucal*. 2018; 23(2):e180-7.
2. Gill JS, Gill S, Bhardwaj A, Grover HS. Oral Haemangioma. *Case Rep Med*. 2012; 347939.
3. Kamala KA, Ashok L, Sujatha GP. Cavernous hemangioma of the tongue: A rare case report. *Contemp Clin Dent*. 2014; 5(1):95-8.
4. Queiroz SIML, de Assis GM, Silvestre VD, Germano AR, da Silva JSP. Treatment of oral hemangioma with sclerotherapy: Case report. *J Vasc Bras*. 2014; 13(3):249-53.
5. Aitha H, Kubbi JR, Gantala R, Korvipati NK. Sclerotherapy: A conservative approach in the treatment of oral hemangiomas. *J Indian Acad Oral Med Radiol*. 2015; 27(2):291-3.
6. Newadkar UR. Oral hemangioma or vascular malformation: Different entities! *J Indian Acad Oral Med Radiol*. 2015; 27(3):497-9.
7. Hong SK, Lee HJ, Seo JK, Lee D, Hwang SW, Sung HS. Reactive vascular lesions treated using ethanolamine oleate sclerotherapy. *Dermatol Surg*. 2010; 36(7):1148-52.
8. Kato CNAO, Ribeiro MC, do Amaral MBF, Grossmann SMC, de Aguiar MCF, Mesquita RA. Experience with 5% ethanolamine oleate for sclerotherapy of oral vascular anomalies: A cohort of 15 consecutive patients. *J Craniomaxillofac Surg*. 2019; 47(1):106-11.
9. Henriques ÁCG, Vidal MTA, Gurgel CA, Rocha SLD, Júnior BC, de Azevedo RA, dos Santos JN. Epithelioid hemangioma in the oral mucosa – A case report. *Srp Arh Celok Lek*. 2016; 144(9-10):535-40.
10. Kumari VR, Vallabhan CG, Geetha S, Nair MS, Jacob TV. Atypical presentation of capillary hemangioma in oral cavity- A case report. *J Clin Diagn Res*. 2015; 9(10):ZD26-8.
11. DeHart A, Richter G. Hemangioma: Recent Advances. *F1000Res*. 2019; 8:F1000 Faculty Rev-1926.
12. Jain S, Singaraju S, Singaraju M. Central hemangioma: A case report and review of literature. *J Indian Soc Pedod Prev Dent*. 2016; 34(1):87-91.
13. Ademi Abdyli R, Abdyli Y, Perjuci F, Gashi A, Agani Z, Ahmedi J. Sclerotherapy of intraoral superficial hemangioma. *Case Rep Dent*. 2016; 2016:4320102.
14. Parisi D, Ciancio F, Cagiano L, Rucci M, Annacontini L, Portincasa A. Hemangioma of the oral and perioral region: Nd:YAG vs surgery. *Ann Ital Chir*. 2016; 2578:S2239253X16025780.
15. Oliveira MMM, da Silva BA. Sclerotherapy as treatment of lingual hemangioma: Clinical case report. *Rev Gaúch Odontol*. 2020; 68:e20200017.

(Received March 25, 2022; Accepted February 9, 2023)